National Museum of Health and Medicine

Otis Historical Archives

OHA 201.05
Jex Medical Illustration Collection

Date of Records: 1917-1926

Size: 1 Box

Finding Aid: Revised by Eric W. Boyle (2012)

Access and Use: The Otis Historical Archives is committed to providing open access to its collections as far as possible within the limits of privacy and confidentiality. Access to this collection is at the discretion of the Otis Historical Archives and material contained within the records may be subject to review before access is granted. Files containing private patient information and protected administrative and grant records are currently closed to researchers.

Series/Scope and Content Note: Garnet W. Jex (October 19, 1895-September 21, 1979), a resident of the Washington D.C. area for 79 years, was recognized locally for his landscape paintings beginning with his first exhibit in 1921. After participating in World War I with the U.S. Army as a medical illustrator, he went on to receive his B.A. and M.A. degrees in Fine Arts from George Washington University. Jex worked as a medical illustrator for the Army Medical Corps for 2 years. Subsequently, he served as art editor of Nature Magazine from 1927-31. Later, the U.S. Public Health Service employed Jex for 26 years as an artist/designer. He ended his career at the U.S. Bureau of State Services in 1962. After his retirement, he dedicated his time to Civil War scholars' groups such as the Civil War Round Table where he served as president in 1967 and 1968. Jex died of a stroke at the age of 83. (Biographical information courtesy of the National Museum of American Art Library which provided Jex's obituary from *The Washington Star*, September 28, 1979.) This collection has been folded into and co-located with OHA 229: Medical Illustrations Collection.

BOX AND CONTENT LIST

Box 026 of OHA 229:

00001: Background Information for Garnet W. Jex

00002: Hernia of Ileum Behind Postoperative Adhesion Between Cecum and Ileum. Acc. #23070. [Pathology code #63543.941 included on image]. 1925. Graphite and ink.

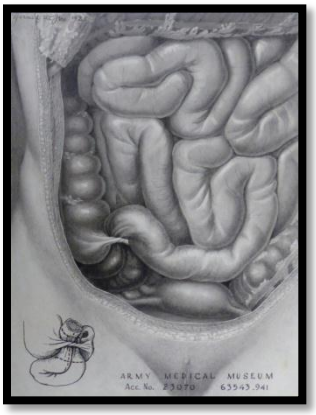

00003: Cystitis Granulosa, 1917-19, Item #2-2

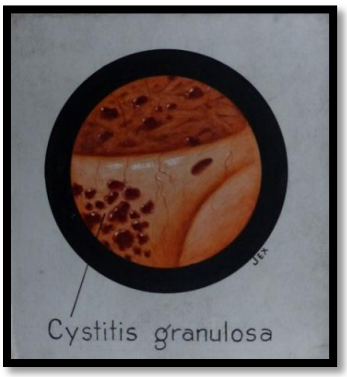

00004: Ureteral Orifice, 1917-19, Item #3-2

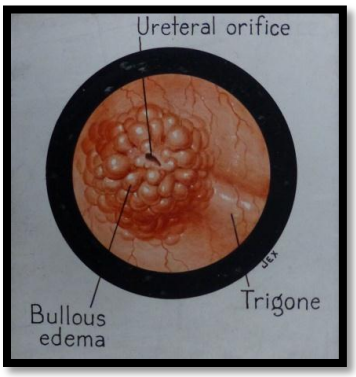

00005: Intravascular Tubercle, 1925, Item #4-2

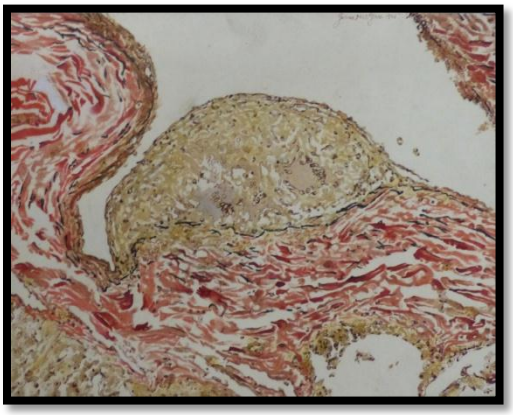

00006: Anatomical Relations of Muscles and Internal Condyle, Col. Keller's Knee, 1925, Item # 5-2



00007: Col. Keller's Knee: Tendons Ready for Passage, 1926, Item # 6-2

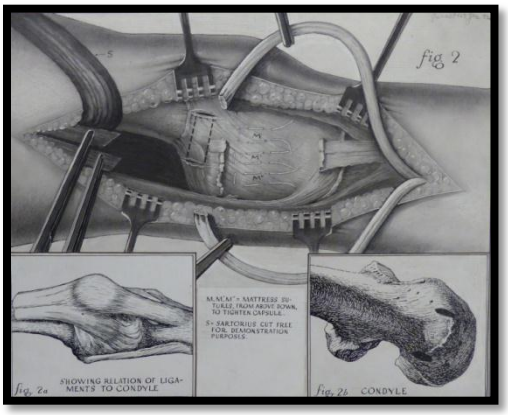

00008: Col. Keller's Knee: Tendons Passed Through and Sutured, 1926, Item #7-2

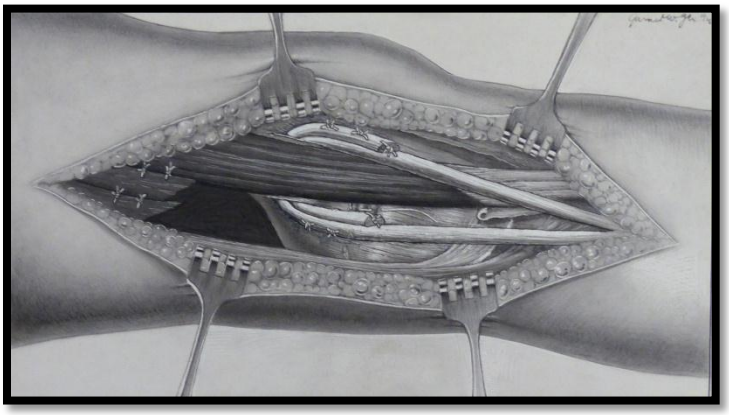

00009: Notes and Sketches on Knee Case Series, Item #8-2

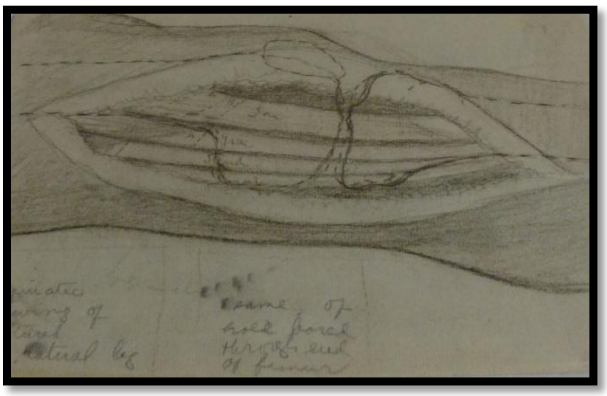

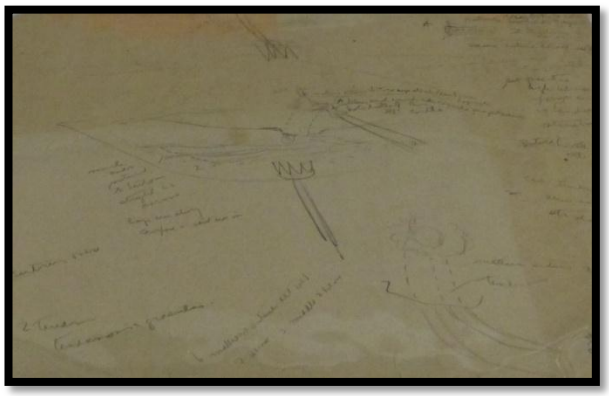

00010: Tunnel Graft Illustrated, Acc. #32498, 4 Boards, 1917-19, Item #9-2

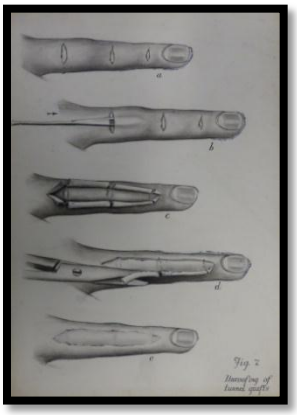

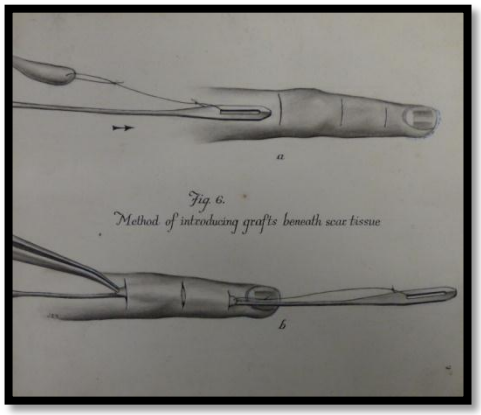

00011: Hematochromatosis: Portions of Liver, Kidney, Heart, Pancreas and Adrenal Glands Showing Normal and Iron Stained Reaction in Hematochromatosis, Acc. #19837, 1924. Item #10-2

00012: Adenocarcinoma of Lung, Acc #21203, Walter Reed Hospital, Nolan, 1923-24, Item #2-1

00013: Adenocarcinoma of Lung, Acc #21203, Walter Reed Hospital, Nolan, 1923-24, Item #3-1

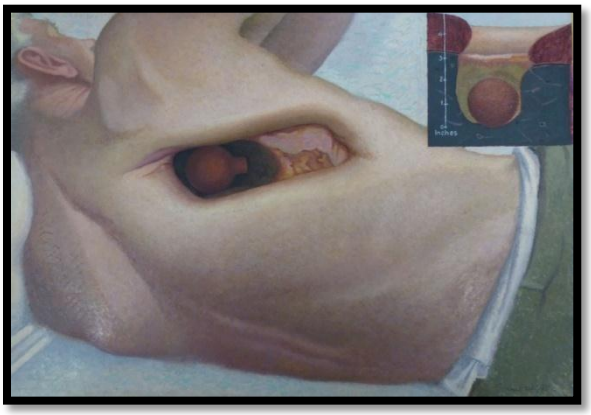

00014: Adenocarcinoma of Lung, Acc #21203, Walter Reed Hospital, Nolan, 1923-24, Item #4-1

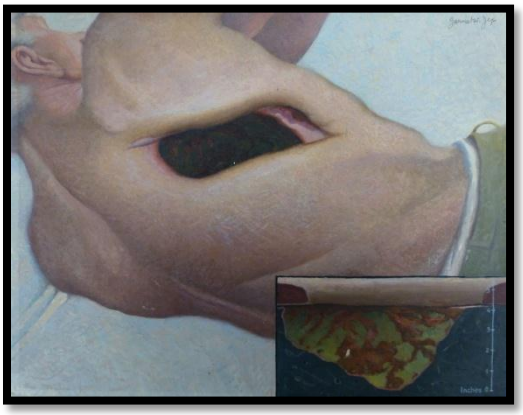

00015: Inguinal Hernia . Drawn for Col. Keller. Acc. #42939-42941. 1926. Graphite and ink. (3 in series). [Each image paired with a corresponding photograph].

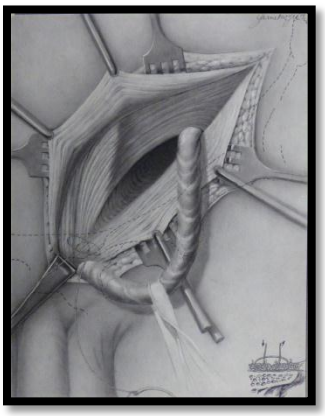

00016: Inguinal Hernia, No. 42940, 1926, Figure 2

00017: Inguinal Hernia, No. 42941, 1926, Figure 3

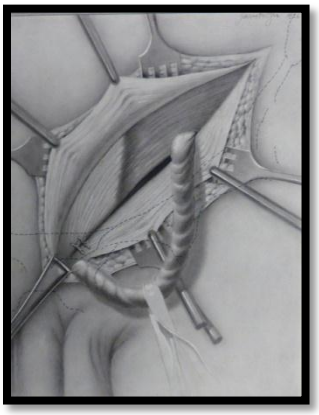

00018: Notes on Inguinal Hernia, Sketches and Photographs, included are 11 photographs taken during operation. 19 unbound encapsulated sheets and 1 sheet of photographs.

00019: Unidentified Surgical Procedure, Col. Herbert Williams, Acc #32645, 1917-19

00020: Surgical Repair of Arm, Lt. Maxwell Balfour, Acc #32644, 1917-19

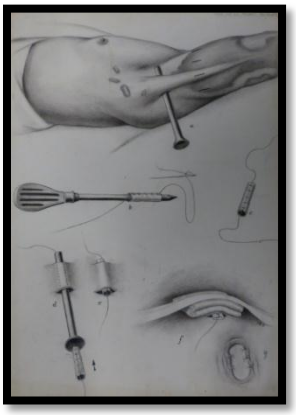

00021: Oral Surgery, Acc. #42957. Drawn for Max Parrish. July 23, 1926.

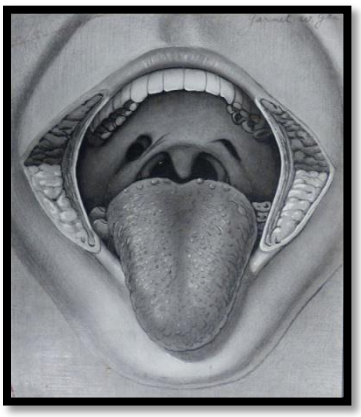
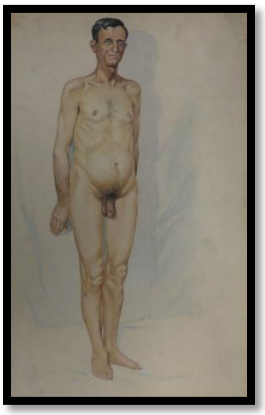
00022: Skin Pigmentation, Mr. Silverman @ Georgetown University Hospital, Jan-Feb 1932